

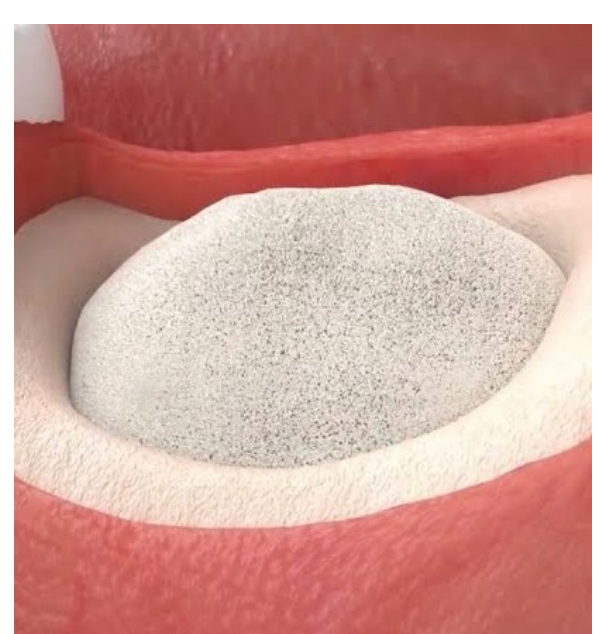INTRODUCTION

- Alveolar ridge preservation (ARP) can be performed using various bone graft materials, but it is difficult to maintain the shape of the membrane and particulate bone graft material when a wide area or a vertical bone defect is formed.
- In contrast, the moldable bone graft material has excellent adhesion and stability to the bone with flexible manipulability of the operator, so that the bone graft is useful for preventing movement of particles during the healing phase.
- This study aimed to compare and evaluate the differences in radiological and histological outcomes of ARP using particulate bone graft material and moldable bone graft material.

METHODS & MATERIAL

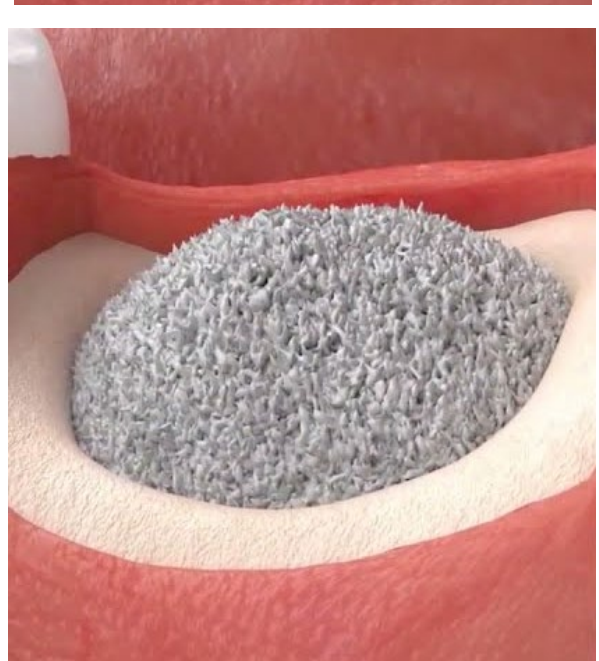- The ARP was performed on 36 patients randomly assigned to two groups. (IRB number: 2-2021-0037).

Bone graft type used in the study



SBX group (n=18)

- Material: S1 (MedPark, Busan, Korea)
- Volume: 0.5g
- Membrane: 13*25mm Bio-Gide



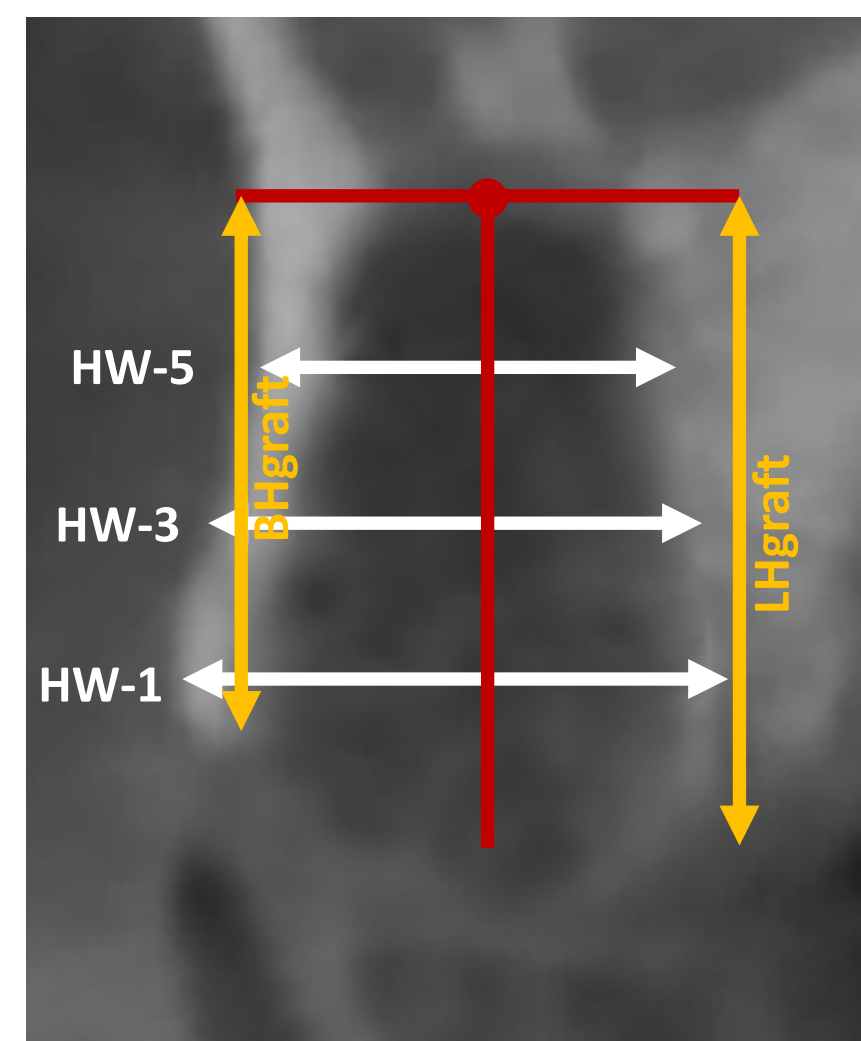
PBX group (n=18)

- Material: Bio-Oss (Geistlich Pharma AG, Wolhusen, Switzerland)
- Volume: 0.5g
- Membrane: 13*25mm Bio-Gide

- CBCT and periapical radiographs were taken before extraction (T1), after extraction (T2; periapical radiograph only), after ARP (T3), and 5 months after ARP (T4) for radiological evaluation.
- In addition, during implant surgery at T4 bone was collected from the center of the extraction socket using a trephine bur, and histological outcomes were compared.

Radiographic analysis


- The measurements were made at baseline and at 5 months using the same reference points and lines.
- To set a reference, the most apical point of the extraction socket was defined in the baseline image and two reference lines were subsequently drawn.



- The **vertical reference line** was drawn in the center of the extraction socket crossing the apical reference point.
- The **horizontal reference line** was drawn perpendicular to the vertical line crossing the apical reference point.
- Height of the alveolar** at the midbuccal (BH) and midlingual (LH)
- Horizontal ridge width measured at three levels** (at -1, -3, -5 mm) below the most coronal aspect of the crest.

Histological analysis

- The harvested bone cores were fixed in 10% buffered neutral formalin.
- Bone cores were decalcified in 10% ethylenediaminetetraacetic acid(EDTA) and embedded in paraffin.
- Serial perpendicular sections were cut along the center of each specimen, and the central-most sections were stained with hematoxylin and eosin (H&E) as well as Masson's trichrome (MT).



- Total augmented area (TAA; %)**
- Residual material area (RMA; %)**
- Connective tissue area (CTA; %)**
- New bone area (NBA; %)**

RESULTS

Table 1. General characteristics of participants

	SBX (n=18)	PBX (n=18)	P
Age (years)	55.28 ± 10.16	51.56 ± 10.45	0.286
Sex			0.738
Male	8 (44.4)	7 (38.9)	
Female	10 (55.6)	11 (61.1)	
Cause of extraction			0.223
Caries	4 (22.2)	6 (33.3)	
Periodontitis	11 (61.1)	7 (38.9)	
Fracture	3 (16.7)	5 (27.8)	
Location			0.502
Maxillary	7 (38.9)	9 (50.0)	
Mandibular	11 (61.1)	9 (50.0)	
Teeth			0.935
Incisor	1 (5.6)	1 (5.6)	
Premolar	6 (33.3)	5 (27.8)	
Molar	11 (61.1)	12 (66.7)	

- Both groups were in their 50s, and the proportion of women was high. In addition, periodontitis p had a high rate of tooth extraction.

Table 2. Changes in ridge height and width over 5 months

	SBX (n=18)	PBX (n=18)	P
Vertical changes (mm)			
BH graft	-0.13 ± 2.01	-0.12 ± 2.23	0.982
LH graft	-0.33 ± 1.00	-0.29 ± 1.05	0.893
Horizontal changes (mm)			
HW-1	-0.12 ± 1.33	-0.16 ± 1.34	0.920
HW-2	-0.87 ± 1.00	-0.96 ± 1.00	0.881
HW-5	-0.41 ± 1.77	-0.23 ± 1.71	0.464

- There was no statistically significant difference between groups at the measured level of change from baseline to 5 months.

Table 3. Histomorphometric analysis (Mean ± SD)

	SBX (n=18)	PBX (n=18)	P
%NBA	11.95 ± 8.79	14.42 ± 7.22	0.379
%RMA	26.65 ± 7.40	25.83 ± 7.42	0.749
%CTA	61.39 ± 8.03	59.75 ± 7.32	0.538

%NBV, percent new bone area; %RMA, percent residual materials area; %CTA, percent connective tissue area

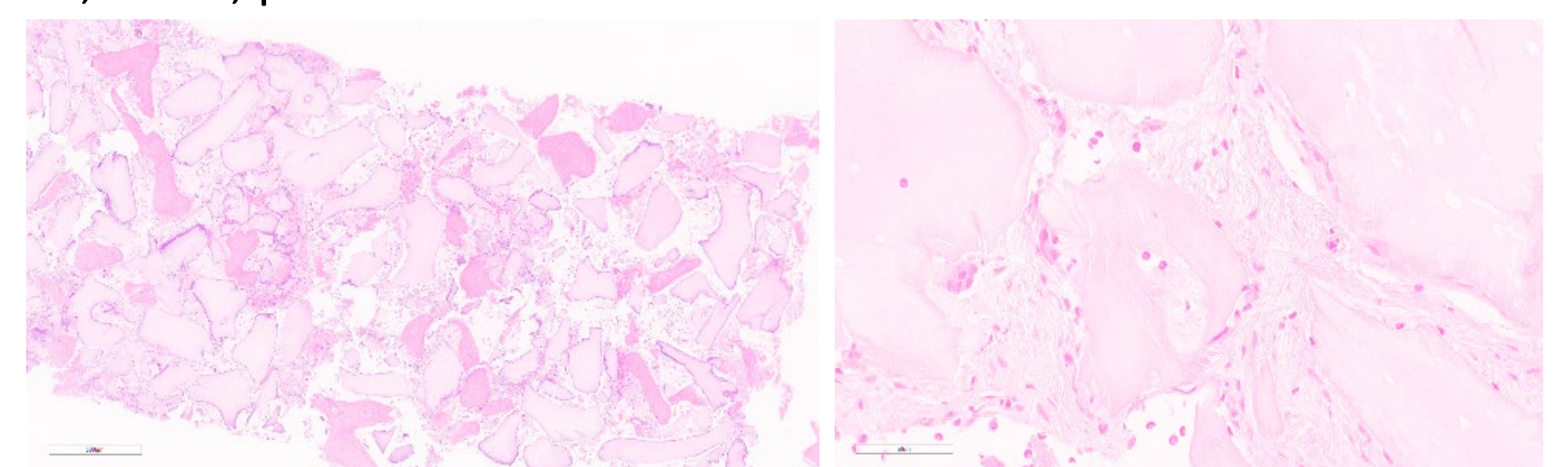


Figure 1. HE staining of the SBX group

- New bone was formed as a whole, and many osteoclasts & osteoblasts were observed around the bone graft material.

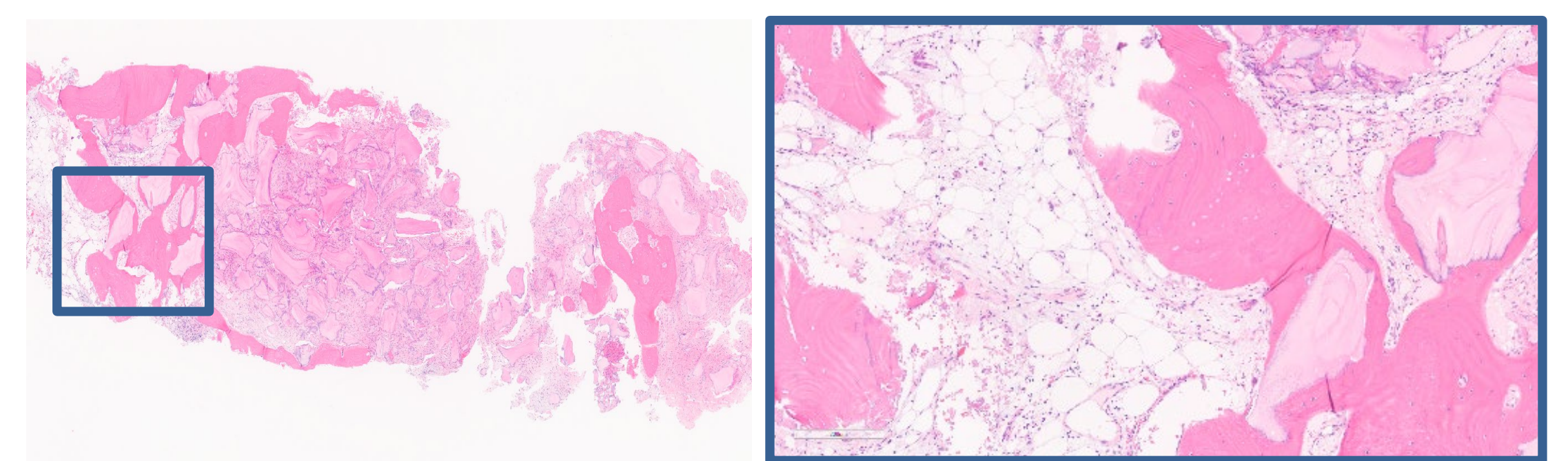


Figure 2. HE staining of the SBX group

- More new bone was formed around the graft material located in the area in contact with autogenous bone, and mature bone and immature woven bone were observed in the form of islands.

CONCLUSION

- This study showed that the moldable bone graft material was helpful in maintaining the alveolar bone volume at a similar level and can form new bone compared to the particulate bone graft material.
- However, as this study observed for a relatively short period of time, a long-term follow-up study to confirm implant stability after implant placement will be needed in further studies.